Reference when publishing to primary publication in cosmetic dentistry 2/2010

Inactive habit

Loss of incisal tooth structure in a 33-year-old patient caused by onychophagia (nail-biting) in his youth

The 32-year-old male patient had a nail-biting habit in his youth. This habit resulted in an abraded, concave incisal edge contour on tooth 11 (Fig. 1). General and specific case history involved analysis of any extended directional movement of the mandible caused by the abrasion as well as a brief check of the functions. The patient was asked to recreate the original movement patterns in order to provide the operator with a picture of the parafunctional directions of movement. The patient was able, without any effort, to assume a position in which there was maximum contact between the upper and lower teeth in the lateroprotrusive position of the mandible. The patient did say, however, that he had given up his earlier habit. This statement led to the conclusion that these mandibular movements were embedded in the neuromuscular loop control and may have been unconsciously adopted by the patient. If a person is aware of movements, self-will causes a control mechanism to intervene. This allows these tooth movements to be avoided (self-protection) due to awareness of the consequences.

Before treatment, analyses were also performed in the special case history with the aid of a function block. Abrasions on the teeth of the patient provided clinical indications of a dysfunction. The causes of the abrasions were subsequently clarified by diagnosis of the craniomandibular system. This type of painful, dysfunction was not detected by the patient, so that it could be assumed that it involved an internalised, tolerated habit in the movement pattern.

Fig. 1 Initial findings with visible reduction of the incisal edge of the right central incisor tooth 11. Fig. 2 In a direct comparison, the change was projected schematically on the photograph using a reconstructive build-up in order to use the expected reconstruction for planning or advising the patient.

Fig. 3 Patient in centric bite relation with maximum intercuspation. The lateral incisors are slightly abraded.

Fig. 4 Patient in lateroprotrusion; there is maximum incisal contact relationship between tooth 11 and teeth 41/31. As a result, the upper incisor and the lower incisors have lost tooth structure.

Fig. 5 The same position of the teeth photographed from another angle highlights the overlapping and exact contact relationship between the antagonists after abrasion.

Fig. 6 Mandible in retrusion. Parafunctional movements caused damage to the incisal edges of the anterior teeth and canines, which were involved in the movements.

The current status was evaluated following the official assessment (Fig. 7-10). An aesthetically unsatisfactory situation was initially analysed, i.e. visually observed from different directions. The position of the anterior teeth, in particular, was to be noted and documented (in study models) during analysis in order to reconstruct the shape according to the original tooth position. This makes it possible to produce a morphological, anatomical reconstruction. Further examination of the defect from the incisal aspect was also useful, as this was used to determine the dimensions of the incisal width (from labial to palatal) of tooth 11. These dimensions provided information about the available layer thickness for the subsequent composite restoration. If the natural surfaces and contours are reproduced accurately, anatomical surface structures in the incisal region produce a lively interplay of light reflection areas in the same way as the labial sections, making the restoration virtually "undetectable". The shade value of the adjacent teeth was compared with that of the tooth to be reconstructed to ensure integration in the dentition. Different angles of view and sources of light, such as pure daylight or viewing the teeth without the surgical light, provide information about the alternating shade values of an anterior arch. If these vary too much, bleaching of individual teeth can help to produce a uniform shade gradient. This option should be offered as a choice to a patient following explanation and before the beginning of treatment. In the case of anterior teeth with very differing shades, bleaching makes it considerably easier to fabricate a composite restoration with a matching shade.

Fig. 7-9 The initial situation with concave structure loss on tooth 11 viewed from different angles. Tooth 11 appears lighter than the adjacent teeth.

Fig. 10 The incisal view allows assessment of the further palatal progression of the defect.

The shade value of teeth dehydrated during treatment no longer corresponds to that of the original shade; the teeth become much lighter. The shade of the tooth to be reconstructed should therefore be selected prior to treatment, particularly when a rubber dam is to be used during treatment. Shade guides or dental spectrophotometers are recommended for selecting the shade. It is also acceptable, however, to apply and cure a sample of the composite shade to the unetched, moist adjacent tooth. The sample does not bond with the enamel and, following polymerisation, the shade can be compared with the adjacent tooth and then the sample can be easily removed. With this patient the shade sample was applied to the lower anterior teeth. (Fig. 11). A mock-up can also be used as an additional check of the shade (Fig. 12). This is the method of choice as a preparatory measure for filling treatment. The composite was applied to the unprepared enamel (Fig.13). The palatal-incisal contours of the tooth were built up and the incisal was optimised to produce a symmetrical, virtually anatomical mirror image of the adjacent tooth. Before the final applied layer was cured, the patient was asked to protrude the mandible in order to shape the uncured composite (Fig. 14 and 15).

Fig. 11 In the protrusive position of the mandible the abraded incisal edges were evaluated in comparison with teeth 31 and 41. When taking the shade, two opaque dentine shades (OD and OM from the Charisma Diamond composite system, Heraeus Kulzer GmbH) were applied to the lower anterior teeth to enable selection of a matching shade. The slightly darker OD shade, which is on the left as viewed by the observer, was selected. The OM shade looked slightly lighter and more luminous.

Fig. 12 The initial layer was applied to incisal edge for fabricating the mock-up.....
Fig. 13. .....and built up optimally to a mirror image of the adjacent tooth.

Fig. 14 The composite was matched to the length of tooth 21. An initial check of the basic shade was made. Fig. 15 The patient was asked to move the mandible carefully towards the ventral with the teeth in contact in order to avoid interference in contact with the subsequent permanent restoration during protrusive excursions of the mandible. The final layer of the material had not been cured at this stage and could still be adapted to the situation by plastic deformation. The material was only polymerised once the mandible was in maximum protrusion. This measure greatly facilitated subsequent preparation.

Preparatory measures of this type facilitate subsequent procedures. Temporary fabrication of an anterior build-up can be used for prognosis at the consultation appointment and is excellent for providing the patient with an idea of the outcome to be expected. To ensure that the prepared shape could be reproduced at another appointment, a silicone overcast impression of the mock-up was taken. The impression did not cover the incisal edges, so that the labial aspect could be built up on the silicone overcast during treatment (Fig. 16/17). The silicone overcast was stored in the practice with the diagnostic documents of the patient and was available as required (Fig. 18). The usual techniques were used for the subsequent procedure. The area of the defect was prepared to enable a smooth transition (Fig. 19) of the composite restoration to the residual tooth. Teflon strips were used to protect the enamel of the adjacent teeth against the effects of conditioning with phosphoric acid (Fig. 20). Following etching (Fig. 21), the area was conditioned with GLUMA 2BOND (Heraeus Kulzer GmbH) using a wetted Applitip (Fig. 22). After curing, the silicone overcast was pressed onto the tooth surfaces palatally and held in position. If impressions of the lower teeth have been incorporated in the overcast to stabilise the position during fabrication of this type of silicone overcast, the patient is asked to bite slightly and apply pressure to the silicone overcast to hold it in the optimal position. (Fabrication: a cotton wool roll is placed between the right and left rest areas during fabrication of a silicone overcast and the patient is asked to bite down slightly. This locks the

bite and impressions of the teeth from the opposing jaw are incorporated in the silicone overcast). The first layer was applied using the Charisma Diamond OD shade (Heraeus Kulzer GmbH) (Fig. 23). The material was applied in small portions with a Heidemann spatula to the palatal wall of the silicone overcast and spread out on the overcast to the incisal. Alternatively, a thin layer of composite can be applied to the silicone overcast and the overcast with the composite layer can then be pressed against the palatal structure in the usual way. In this case the opaque shade components OD (Opaque Dark) provided an adequate shade match to the natural shade of the residual tooth. No transparent sections were detected in the incisal region during the earlier shade analysis. There were light, predominantly whitish enamel sections on the surface of the tooth. To ensure adaptation to this shade interplay, no transparent areas were to be built up in this region, as this could impair the result because it would produce a greyish appearance. (Transparent areas do not reflect light as effectively and consequently often appear grey). Following removal of the overcast (Fig. 24), the material still appeared slightly transparent due to the minimal layer thickness. This wall was used as a fixed template for subsequent overlaying. The stability of the wall allowed the operator to build up the material precisely.

To ensure an optimal shade match, further layering was completed using the same material as the layer already applied (Fig. 25). The increase in layer thickness produced a marked, visible increase in the opacity. The special filling particle technology of the Charisma Diamond material produces the so-called chameleon effect when matching the shade, so that shade A2 could be used for the next layer (Fig. 26). This was also used as the final layer, as an optimal shade match had already been attained at this stage using A2. In this case, however, a more vital appearance of the restoration was to be attained by an additional application of the bleach shade BL (Fig. 27). The aim was to imitate the light, veil-like characteristics in the natural, upper incisal areas. The incisal region was intentionally overcontoured (Fig. 28) in order to create a better incisal edge contour during preparation. This proved highly effective, as different aesthetic variations were tried using this technique and the contour could be optimally matched to the overall aesthetic appearance.

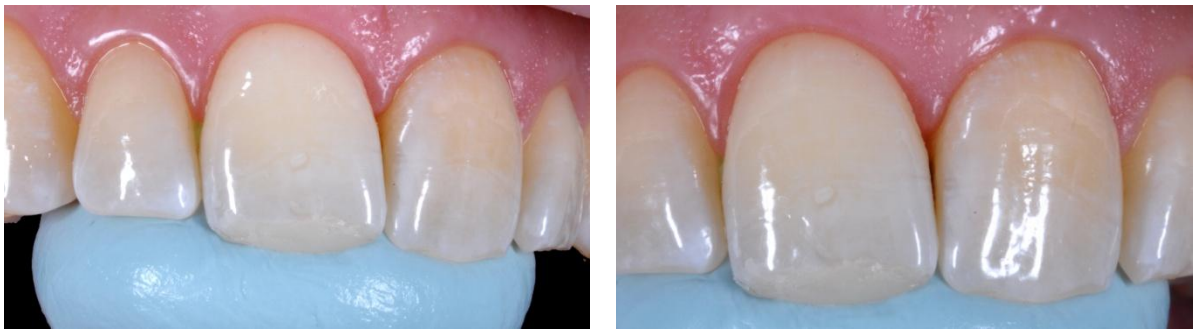

Fig. 16 +17 A silicone impression was taken of the mock-up palatally for producing a silicone overcast. It is important to ensure that the material is not pressed over the incisal edge, so that it is easier to apply and adapt composite on the silicone overcast at a later stage. The overcast was available in the further stages of treatment as an open template.

Fig. 18 The silicone overcast, with an impression of the palatal structure, was available for further processing. Any overcontouring of the labial incisal surface in silicone was reduced using a scalpel. A precise working template, with a sharp incisal margin in the silicone overcast, helps during the build-up procedure. Fig. 19 A bevel of approx. 30° was prepared in the enamel of the cavity margins/ fracture margins; rough irregularities on the incisal edge were smoothed. ***Fig. 20*** *Before the enamel was conditioned with phosphoric acid, Teflon strips were used to protect the adjacent structures against any damaging effects.* ***Fig. 21*** *The entire incisal surface of the tooth to be treated was coated with etching gel.*

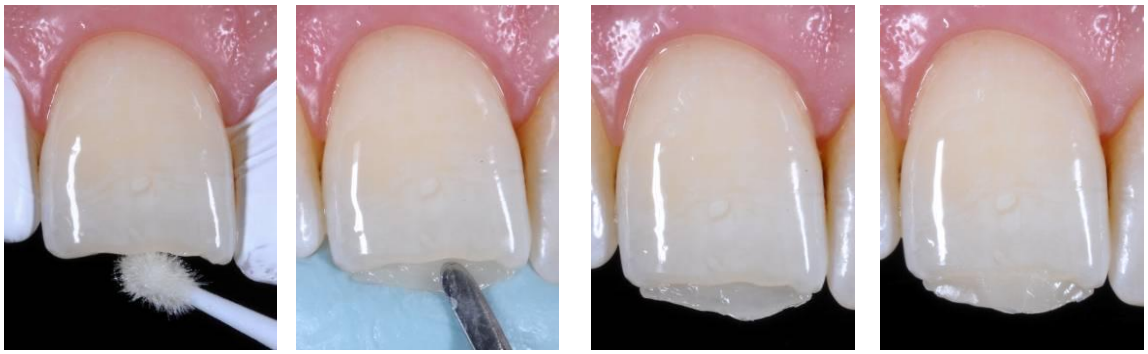

Fig. 22 *Bonder was applied to the etched surface.* ***Fig. 23*** *The silicone overcast was pressed onto the dentition palatally and coated with the first material component Charisma Diamond (shade OD). The composite was applied and distributed (thixotropy) onto the overcast with a Heidemann spatula exerting light pressure and vibrating movements. This application technique ensures bubble-free adaptation of the composite to the silicone overcast and tooth structure.* ***Fig. 24*** *The finished wall with the first opaque shade component was the primary light block because it is an opaque material component. The basic shape of the tooth produced at the first stage was now ready for further processing.* ***Fig. 25*** *The incisal area was almost completely built up (up to 70%) in subsequent layering. Space was left labially for the next layer.*

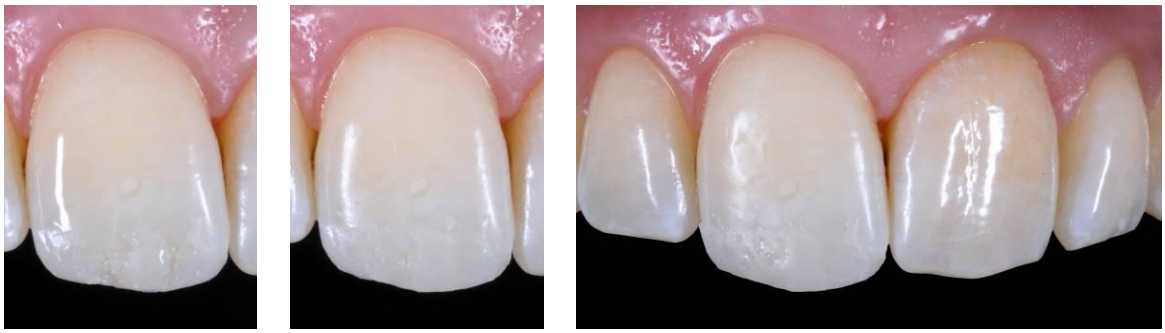

Fig. 26 *Shade A2 of Charisma Diamond was applied in a mamelon-like structure (**Fig. 27)** to allow space for the layer of BL shade. Layering of the BL shade created an invisible transition to the rest of the enamel.* ***Fig. 28*** *The length of the slightly thicker build-up of tooth 11 is very noticeable in comparison with the adjacent tooth.*

The quality of the build-up was such that the labial surface virtually corresponded to the final appearance of the tooth. If the composite is spread out smoothly and bubble-free to ensure a homogeneous surface, it greatly facilitates subsequent preparation and polishing. A universal, two-step diamond polishing system was used**.** The coarse prepolishers can be used for smoothing any roughness and for fine, gradual preparation of the junctions to the tooth structure. Aspects of the shape can also be adjusted, as it is also possible to remove a greater amount of material with the rubber polishers depending on the pressure applied. The composite should be prepared so that the rotation of the instrument is directed away from the filling material towards the tooth structure to remove the material. This makes it possible to prepare very thin tapering junctions. The high-gloss polisher, produces a very fine glaze on the surface and is used as the final instrument for polishing to a high lustre.

Fig. 29 *The prepared tooth surfaces with continuation of the reflection/ light ridges of the tooth into the composite restoration. Natural aspects of the shape were also taken into consideration and the incisal edge was contoured according to aesthetic and functional criteria. The surface of the tooth was already prepolished.* ***Fig. 30*** *Viewed from a different angle; the incisal edges are harmonious and their distinctive characteristics imitate those of the adjacent tooth.*

Fig. 31 *In centric jaw relationship the shade of the restoration appears integrated when compared with the other teeth. The width and length of the tooth have been physiologically proportioned.* ***Fig. 32*** *The dental arch looks harmonious when viewed from the front.*

Fig. 33 *Adequate space was created so that there was uninterrupted, harmonious excursion of the mandible ventrally (protrusion). The incisal contacts were prepared to ensure balanced, uniform contact points of the two incisors with the antagonist teeth in the mandible.* ***Fig. 34*** *The contact areas of tooth 11 produced in the protrusive excursion can be seen when viewed from the incisal. These are smoothed further after final preparation and polishing.*

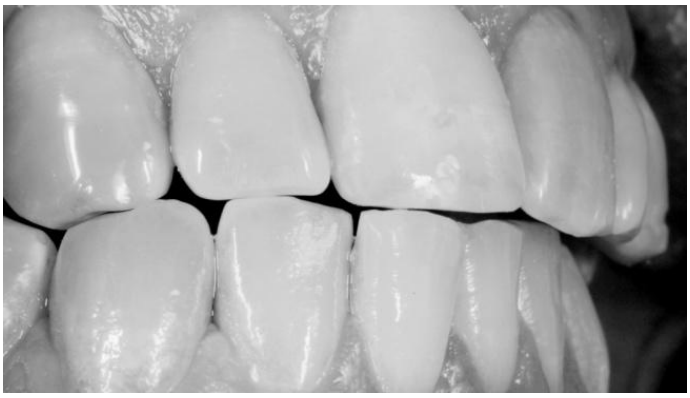

Fig. 35 *During lateroprotrusive excursion the newly built up incisal edge of tooth 11 slides smoothly, without interference, over the antagonist teeth.*

Apart from using modern materials with their technical advantages, which enable an exceptionally stable and consequently highly aesthetic restoration, basic case history findings are also essential when fabricating anterior composite restorations. The cause of the defect to the area to be reconstructed must be evaluated and examined to prevent recurrence of a degenerative development for the tooth. If this has been the result of functional disorders, the restoration of a defect will be abraded or fractured if the causes are ignored. Functional analysis and possible therapy required for reprogramming the stomatognathic system are indicated prior to any functional reconstruction. Long-term success is guaranteed with the use of highly developed, well-researched conditioners (e.g. GLUMA 2BOND) and composites (e.g. Charisma Diamond) currently on the market which have highly aesthetic properties and also produce outstanding results with regard to stability and elasticity.

Successful restorations are now possible using a material such as **Charisma Diamond,** a new universal nanohybrid composite, which has a low shrinkage and high strength. It also produces a shade match with only two layers due to its chameleon effect.

Author: Ulf Krueger-Janson 2009